

2. *Idem*: Metabolic abnormalities of vitamin B₆ and magnesium in alcohol-induced sideroblastic anemia. *Prog Clin Biol Res* 1:621-642, 1975
3. Hines JD, Cowan DH: Studies on the pathogenesis of alcohol-induced sideroblastic bone-marrow abnormalities. *N Engl J Med* 283:441-446, 1970
4. Chern CJ, Beutler E: Assay for human erythrocyte pyridoxine kinase. *Anal Biochem* 67:97-109, 1975
5. Beutler E: *Red Cell Metabolism: A manual of biochemical methods*. Second edition. New York, Grune and Stratton, 1975
6. Chern CJ, Beutler E: Pyridoxal kinase: decreased activity in red blood cells of Afro-Americans. *Science* 187:1084-1086, 1975
7. *Idem*: Biochemical and electrophoretic studies on erythrocyte pyridoxine kinase in white and black Americans. *Am J Hum Genet* 28:9-17, 1976
8. Jandl JH: The anemia of liver disease: observations on its mechanism. *J Clin Invest* 34:390-404, 1955
9. Douglass CC, Twomey JJ: Transient stomatocytosis with hemolysis: a previously unrecognized complication of alcoholism. *Ann Intern Med* 72:159-164, 1970
10. Hines JD: Hematologic abnormalities involving vitamin B₆ and folate metabolism in alcoholic subjects. *Ann NY Acad Sci* 252:316-327, 1975
11. Hines JD, Love D: Abnormal vitamin B₆ metabolism in sideroblastic anemia: effect of pyridoxal phosphate (PLP) therapy. *Clin Res* 23:403a, 1975
12. Lumeng L, Li TK: Vitamin B₆ metabolism in chronic alcohol abuse: pyridoxal phosphate levels in plasma and the effects of acetaldehyde on pyridoxal phosphate synthesis and degradation in human erythrocytes. *J Clin Invest* 53:693-704, 1974
13. Solomon L, Hillman RS: Vitamin B₆ metabolism in alcohol-induced and idiopathic sideroblastic anemia. American Society of Hematology 18th Annual Meeting Dallas, Texas, December 6-9, 1975
14. Srivastava SK, Beutler E: A new fluorometric method for the determination of pyridoxal 5'-phosphate. *Biochim Biophys Acta* 304:765-773, 1973
15. Hines JD, Love DS, Peart MB: Determination of serum and blood pyridoxal phosphate concentrations with purified rabbit skeletal muscle apophosphorylase b. *J Lab Clin Med* 73:343-349, 1969
16. Jacobs A, Cavill IAJ, Hughes JNP: Erythrocyte transaminase activity: effect of age, sex, and vitamin B₆ supplementation. *Am J Clin Nutr* 21:502-507, 1968
17. Hoorn RKJ, Flikweert JP, Westerink D: Vitamin B-1, B-2 and B-6 deficiencies in geriatric patients, measured by coenzyme stimulation of enzyme activities. *Clin Chim Acta* 61:151-162, 1975
18. Hamfelt A: Pyridoxal kinase activity in blood cells. *Clin Chim Acta* 16:7-18, 1967
19. Chern CJ, Beutler E: Purification and characterization of human erythrocyte pyridoxine kinase. *Clin Chim Acta* 61:353-365, 1975

MERCURY EMBOLIZATION OF THE LUNG

BARTOLOME CELLI, M.D., AND M. ANEES KHAN, M.D.

ALTHOUGH accidental or suicidal mercurial embolization of systemic or pulmonary vasculature has occasionally been described,¹⁻⁵ self-administration intravenously of metallic mercury in the hope of attaining muscular strength of an athlete is unusual. In contrast, the practice, among the laity, of deliberate intramuscular injection of metallic mercury under the false hope of developing stronger musculature has been informally recognized in Latin and South America (Cortez C: personal communication), but sequelae have not been described. We report on a case of acute lung disease that developed in a young amateur boxer after deliberate intravenous injection of 20 ml of metallic mercury.

From the Pulmonary Disease Section, Department of Medicine, Thorncliffe Memorial Laboratory, Boston City Hospital, and Boston University School of Medicine (address reprint requests to Dr. Khan at Boston City Hospital, 818 Harrison Ave., Boston, MA 02118).

CASE REPORT

A 14-year-old black male boxer, recently arrived from British Honduras, was admitted to the Boston City Hospital because of general malaise, pleuritic chest pain and shortness of breath of 24 hours' duration. Two days previously, while in his native land, he had received an intravenous injection of 20 ml of metallic mercury from a friend in the belief (common among his peers) that infusion of mercury would "strengthen his punches." Although the patient had had occasion to use mercury intramuscularly before, the intravenous injection was a new experiment. He denied having had any ill effects immediately or within the first 24 hours after the injection.

Besides a temperature of 38.3°C, pulse rate of 96 per minute and shallow respirations of 32 per minute, physical examination was unremarkable. A roentgenogram (Fig. 1 and 2) showed diffuse metallic densities simulating arborizing vessels throughout both lung fields. A small pool of metallic density was also seen within the right ventricle. The systemic extension of mercurial embolization was evidenced by the presence of metallic densities on roentgenograms of the abdomen. An arterial-blood gas analysis on room air showed a pH of 7.48, oxygen tension of 60 mm Hg and carbon dioxide tension of 35 mm Hg. Serum chemical findings, including electrolytes, urea nitrogen and creatinine, and liver-function tests, as well as a complete blood count and urinalysis, were unremarkable.

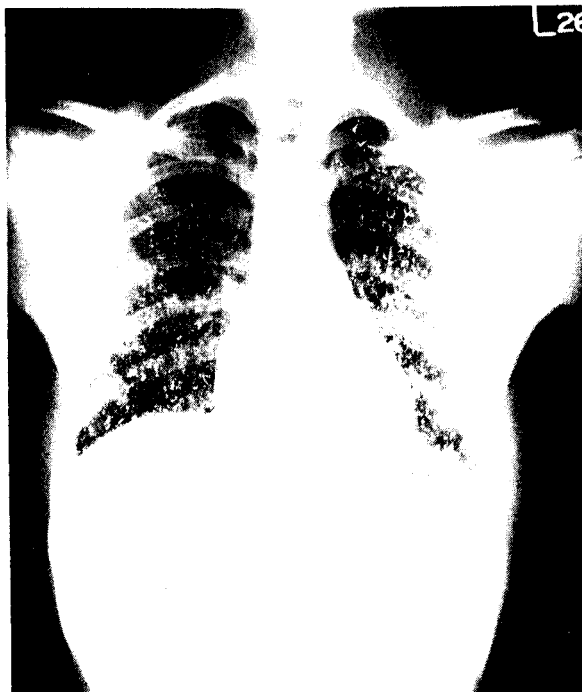


Figure 1. Posteroanterior Roentgenogram, Showing Mercury Emboli throughout Both Lungs. A small collection of the metal is present within the right ventricle.

The patient was treated with nasal oxygen, analgesics and intravenous fluids and showed gradual clinical improvement over two weeks. Hypoxemia and respiratory alkalosis seen on admission completely resolved by the end of the first week. Features of acute or chronic systemic mercury poisoning did not develop. On the 12th hospital day, pulmonary-function tests performed showed (Table 1) a moderate degree of restrictive disease, with marked diminution of diffusing capacity.

Pulmonary-function tests repeated two months and then five months after discharge from the hospital indicated gradual improvement, as did roentgenography. So far, the patient has had no



Figure 2. Close-up Roentgenographic View of the Mercury-Filled Arborizing Vasculature of the Left Lower Lung.

evidence of renal or hepatic damage. A roentgenogram obtained 11 months after the initial insult still showed residual metallic densities in both lung fields.

DISCUSSION

Although mercurialism as an environmental and occupational hazard of modern industry has frequently caused disease in man,⁶ poisoning by metallic mercury is a rare occurrence. Approximately 30 such cases have so far been reported in the literature. Most are accidental — i.e., soft-tissue injury from a broken

Table 1. Serial Pulmonary-Function Tests Two, Eight and 20 Weeks after Mercury Injection.*

TEST	PREDICTED VALUES	ACTUAL VALUES		
		AT 2 WK	AT 8 WK	AT 20 WK
FVC (liters)	3.76	2.01	2.90	3.04
FEV ₁ (liters)	3.23	1.78	2.49	2.93
FEV ₁ (%)	>75	88	85	96
TLC (liters)	4.93	3.01	4.03	5.32
RV (liters)	1.17	1.18	1.21	1.29
DLCO (single breath) (ml/min/mm Hg)	31.7	15.8	—	24.5

*FVC denotes forced vital capacity, FEV₁ forced expiratory vol in 1 sec, TLC total lung capacity, RV residual vol, & DLCO diffusing capacity of lung.

thermometer⁷ or rupture of the mercury-filled bag of an indwelling intestinal tube,^{8,9} causing mild local, sometimes systemic, symptoms of mercury poisoning referable to the central nervous system, the gastrointestinal tract or the kidneys. More recently, accidental arterial embolization has followed blood sampling during use of mercury as a seal in the syringe.¹⁻³ Such mishaps may cause multiple sterile abscesses of the extremity involved.¹ Similarly, accidental mercury embolization of the lungs may result from sampling of venous blood while a mercury seal is being used during cardiac catheterization.³

Suicide attempts by means of mercury injection have occasionally caused death.^{5,10} In the case described by Johnson and his colleagues,⁵ mercury embolization of the lungs clearly made a large contribution to the fatal outcome: a 23-year-old laboratory technician had respiratory failure four days after injecting 1 to 2 ml of mercury into her left forearm; she required intubation and respirator therapy. Mercury embolization of the lungs was confirmed by radiography. Renal failure ultimately developed as well, and she died one month later.

Others have been fortunate to have survived despite mercury embolization of the lungs, with or without evidence of systemic poisoning.^{2,4,10} Only one of these patients, that studied by Conrad et al.,⁴ underwent pulmonary-function evaluation. This 26-year-old radar mechanic had shortness of breath, fever and general weakness for one day. There was roentgenographic evidence of mercury embolism of the lungs, as well as the presence of mercury in the subcutaneous tissue of the left antecubital fossa, the apparent injection site. Pulmonary-function abnormality (vital capacity of 1140 ml and maximum breathing capacity of 47 liters per minute), documented on the fifth hospital day, slowly resolved over a six-week period, although the roentgenographic findings were still present 10 weeks later. Renal damage was evidenced by the presence of protein and white blood cells in the urine, which resolved spontaneously.

Unlike the patients described by Conrad⁴ and Johnson⁵ and their co-workers, our patient did not have clinically detectable renal damage despite a massive dose of mercury. However, a marked ventilatory defect similar to that seen in the patient of Conrad et al. developed, along with a substantial reduction in the diffusing capacity. Resolution of the ventilatory and diffusion abnormalities occurred gradually over a period of 20 weeks, accompanied with roentgenographic improvement. The slow biologic oxidation of metallic mercury is said to result in the formation of soluble salts, which are ultimately excreted via the colon, the kidneys and the salivary glands, thus reducing the total mercury load.³ The elimination of the heavy metal from the tissues may be hastened by the use of certain chelating agents such as dimercaprol or penicillamine.

The deliberate use of mercury for the purpose of developing stronger muscles seems most unusual.

Kern and his colleagues described a 21-year-old boxer-in-training who injected metallic mercury into his arm after his friends' suggestion that quicksilver would make his punches quicker.¹¹ Three months later he had abscess formation at the injection site. Radiographic examination confirmed the presence of mercury within the abscess cavity. Mercury embolization of the lungs did not occur. Although toxic screening provided evidence of mercury absorption from the injection site, systemic effects were not seen.

The origin of this myth eludes us, but there is reason to suspect that the practice of injecting mercury to develop stronger muscles is not uncommon among certain groups in South and Latin America. Our case report documents the presence of yet another variant of this social problem — namely, the practice of injecting mercury intravenously and the pulmonary complications thereof, the prevalence of which also needs to be explored.

REFERENCES

1. Latham W, Lesser GT, Messinger WJ, et al: Peripheral embolism by metallic mercury during arterial blood sampling: report of two cases. *Arch Intern Med* 93:550-555, 1954
2. Schulz E, Beskind H: Systemic deposition of metallic mercury. *J Pediatr* 57:733-737, 1960
3. Buxton JT, Hewitt JC, Gadsden RH et al: Metallic mercury embolism: report of cases. *JAMA* 193:573-575, 1965
4. Conrad ME, Sanford JP, Preston JA: Metallic mercury embolization — clinical and experimental. *Arch Intern Med* 100:59-65, 1957
5. Johnson HRM, Koumides O: Unusual case of mercury poisoning. *Br Med J* 1:340-341, 1967
6. Joselow MM, Louria DB, Browder AA: Mercurialism: environmental and occupational aspects. *Ann Intern Med* 76:119-130, 1972
7. Rachman R: Soft-tissue injury by mercury from a broken thermometer: a case report and review of the literature. *Am J Clin Pathol* 61:296-300, 1974
8. Lindenmuth WW: Fecal fistula due to metallic mercury from a Miller-Abbott tube: report of a case. *JAMA* 141:986-987, 1949
9. Cantor MO: Mercury lost in the gastrointestinal tract: report of unusual case. *JAMA* 146:560-561, 1951
10. Umber: Quecksilber-Embolien der lebenden Lunge durch intravenöse Injektion von metallischem Quecksilber. *Med Klin* 19:35, 1923
11. Kern FB, Condo F, Michel SL: Mercury granuloma with systemic absorption. *JAMA* 222:88-89, 1972

CASE RECORDS OF THE MASSACHUSETTS GENERAL HOSPITAL



Weekly Clinicopathological Exercises

FOUNDED BY RICHARD C. CABOT

ROBERT E. SCULLY, M.D., *Editor*

JAMES J. GALDABINI, M.D., *Associate Editor*

BETTY U. MCNEELY, *Assistant Editor*

Continued preparation of these Case Records has been made possible by a generous grant from Pfizer Pharmaceuticals to the Massachusetts General Hospital.

CASE 42-1976

PRESENTATION OF CASE

First admission. A 49-year-old Venezuelan man was admitted to the hospital because of fever.

Aside from occasional bouts of renal colic he was well until six months previously, when diarrhea developed. Examination of a stool specimen revealed evidence of infestation with *Strongyloides stercoralis* and *Enterobius histolytica* and a small amount of occult blood; there was no evidence of Chagas's disease. Diiodoquin, metronidazole and chlorphenoxamide were administered. One month later, while he was still re-

ceiving treatment, arthralgia occurred, with a daily rise of the temperature to 38°C, accompanied by shaking chills, malaise, anorexia and edema of the hands and feet; no arthritis was found. Two months before admission a cough developed, and an x-ray film of the chest was reported to show an infiltrate in the left lower lobe. Cultures of sputum yielded no pathogenic micro-organisms, and serologic tests for fungal infection were negative. The white-cell count was 20,000, and the erythrocyte sedimentation rate 73 mm per hour. Biopsies of a scalene lymph node and of the deltoid muscle were reported to be negative. The patient passed a renal stone.

Five weeks before admission cardiac evaluation revealed a Grade 2 systolic murmur and S4 and S3 sounds. An electrocardiogram showed first-degree atrioventricular block with nonspecific abnormalities of the ST segments and T waves; a diagnosis of myocarditis with congestive heart failure was made. One month before admission prednisone was begun, with improvement, although a daily low-grade fever persisted. Four days before entry an attempt to taper the dose of prednisone was followed by a rise of the temperature to 38°C, increasing arthralgia and cough. The dose of prednisone was increased, and he was referred to this hospital.

He had been vaccinated with BCG and was known to have a positive tuberculin skin test. During the four months before admission he had lost 12 kg in weight. There was no history of rheumatic fever, diabetes mellitus, myocardial infarction or use of tobacco or alcohol.

The temperature was 37°C, the pulse 100, and the respirations 20. The blood pressure was 125/70 mm Hg.

On examination the patient appeared well and lay flat in bed in no distress. No rash, petechiae or enlarged lymph nodes were observed. The thyroid gland was of normal size. Crackling inspiratory rales were